

# Porcine feasibility and safety study of a new paclitaxel-eluting biliary stent with a Pluronic-containing membrane

## Authors

S. I. Jang<sup>1</sup>, J.-H. Kim<sup>1</sup>, M. Kim<sup>2</sup>, S. Yang<sup>6</sup>, E. A. Jo<sup>3</sup>, J. W. Lee<sup>4</sup>, K. Na<sup>4</sup>, J. M. Kim<sup>5</sup>, S. Jeong<sup>6</sup>, D. H. Lee<sup>2,6</sup>, D. K. Lee<sup>1</sup>

## Institutions

Institutions are listed at the end of article.

## submitted

14. October 2011

## accepted after revision

12. April 2012

## Bibliography

**DOI** <http://dx.doi.org/10.1055/s-0032-1309881>  
Published online: 2.7.2012  
Endoscopy 2012; 44: 825–831  
© Georg Thieme Verlag KG  
Stuttgart · New York  
ISSN 0013-726X

## Corresponding author

**D. K. Lee, MD PhD**

Department of Internal  
Medicine  
Gangnam Severance Hospital  
Yonsei University College of  
Medicine  
712 Eonjuro  
Gangnam-gu  
Seoul 135-720  
Korea  
Fax: +82-2-34633882  
dklee@yuhs.ac

**Background and study aim:** Metal stents for malignant biliary obstruction are susceptible to occlusion by tumor ingrowth or overgrowth. Therefore, we previously reported our use of a metal stent covered with a paclitaxel-incorporated membrane giving an antitumor effect to prevent occlusion from tumor ingrowth. We have also developed a new generation of paclitaxel-eluting biliary stent using a membrane containing Pluronic F-127 for effective drug delivery. The aim of this study was to investigate the safety and efficacy of drug delivery for this newly developed stent in the biliary tract.

**Methods:** Metal stents were coated with paclitaxel and various concentrations of Pluronic F-127 in phosphate-buffered saline solution. Stents containing varying concentrations were placed in the bile ducts of eight pigs divided as follows: group I, 0% Pluronic+0% paclitaxel; group II, 0% Pluronic+10% paclitaxel; group III, 10% Pluronic

+10% paclitaxel; group IV, 20% Pluronic+10% paclitaxel. The histology of the porcine bile duct and the amount of paclitaxel in the porcine serum were examined. The amount of paclitaxel released was also measured in vitro.

**Results:** Histologic changes in the porcine biliary epithelium were acceptable in terms of safety, based on inflammatory cell infiltration and fibrotic reaction. No significant differences in histology were observed between the groups. In the porcine serum analysis, released paclitaxel was detected for 28 days with the 10% Pluronic concentration (group III). However, released paclitaxel was observed for only 7 days in groups II and IV. In the in vitro experiments, long-lasting release of paclitaxel was also noted from the stent with 10% Pluronic.

**Conclusions:** The new paclitaxel-eluting stent with 10% Pluronic F-127 is safe and provides enhanced local drug delivery.

## Introduction

Endoscopic stent insertion is the treatment of choice for unresectable malignant biliary obstruction. Self-expanding metal stents (SEMSs) have been shown to be superior to plastic stents in patency and efficacy [1, 2] although they provide no improvement in survival. However, even metal stents can become occluded over time because of tumor overgrowth, ingrowth, and biliary sludge. Moreover, metal stents merely promote biliary drainage and have no antitumor effect [3]. Therefore, the local application of chemotherapeutic drugs via SEMSs has been proposed as a possible method to prevent tumor ingrowth [4].

We developed a metal stent covered with a paclitaxel-incorporated membrane (MSCPM) and have previously reported the safety and efficacy of this stent in preventing occlusion due to tumor ingrowth by its antitumor effects in the biliary tract [3, 5]. For the MSCPM, paclitaxel was mixed in a

tetrahydrofuran (THF) solution, which is used as a solvent for polyurethane. A coating of the polyurethane/paclitaxel liquid was added to the stent. Polyurethane membranes in intact biliary tracts can be biodegraded by hydrolysis and oxidation [6] and may be damaged because of contact with the continuous flow of bile [4, 7]. Degraded membranes cause the formation of microcracks and holes in the stents, resulting in stent occlusion by tumor ingrowth [7, 8]. Thus, membranes must be protected from biodegradation and the chemotherapeutic agents must remain effectively incorporated in the membrane to maintain a steady release of the drug over an adequate duration [4]. Therefore, we developed a new metal stent covered with a paclitaxel-incorporated membrane (MSCPM-2) using polytetrafluoroethylene (PTFE) as the inner layer for resistance to bile degradation and a polyurethane/Pluronic F-127 mixture as a surfactant for effective incorporation of the

drug into the membrane and its steady release [9]. The aim of the present study was to investigate the safety and efficacy of this new generation of paclitaxel-eluting stent in the biliary tract.

## Materials and methods

### Preparation of the new paclitaxel-eluting stents

The stents used in this study (Niti-S; Taewoong Medical, Gimpo, Korea) were 6 mm wide and up to 20 mm long, the length determined by the size of the lumen in which the composite stents were to be implanted (● Fig. 1). Polyurethane was selected as the covering material because it is widely used for medical purposes and has a good safety record.

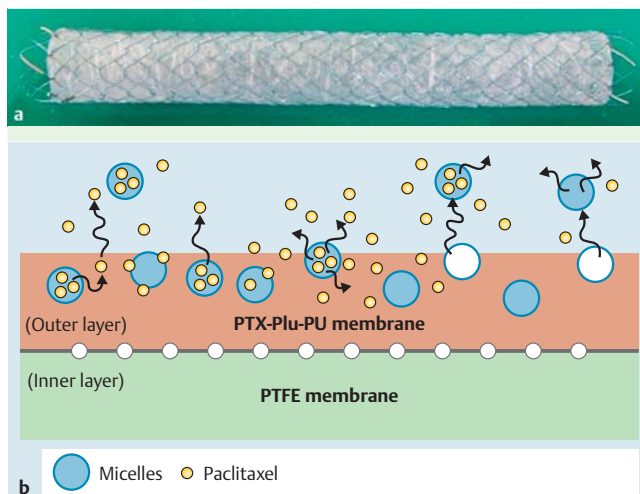
Four sets of paclitaxel-incorporated Pluronic F-127–polyurethane (PTX–Plu–PU)-coated stents with varying concentrations of Pluronic in the membrane were prepared for the in vitro and in vivo studies. Based on a previous study [3], the concentration of paclitaxel in three of the sets of stents, used for the in vivo and in vitro studies, was fixed at 10%; the fourth set formed the control with no paclitaxel or Pluronic present and was used in only the in vivo study.

The coating solution was made from 400 mg of the PTX–Plu–PU polymer and 10 mL of THF. The proportions of the solution in the four sets of PTX–Plu–PU-coated stents were as follows: (i) no paclitaxel/no Pluronic (polyurethane 400 mg+THF 10 mL); (ii) 10% paclitaxel/no Pluronic (polyurethane 360 mg+paclitaxel 40 mg+THF 10 mL); (iii) 10% paclitaxel/10% Pluronic (polyurethane 320 mg+paclitaxel 40 mg+Pluronic 40 mg+THF 10 mL); and (iv) 10% paclitaxel/20% Pluronic (polyurethane 280 mg+paclitaxel 40 mg+Pluronic 80 mg+THF 10 mL).

The coating process was carried out using the dip-coating technique. The dipping solution for the PTX–Plu–PU membrane was made by dissolving the appropriate amount of paclitaxel with the premixed polyurethane and Pluronic in a THF solution. A Teflon bar with a diameter similar to that of the stent was selected. The stent was mounted on the bar and was dipped in a container filled with the mixture of medical-grade polyurethane, Pluronic, and paclitaxel. The coated stents were dried at 40 °C in an oven for 30 minutes to completely remove the solvent.

### Preparation of coated films

Four sets of PTX–Plu–PU films were prepared for the in vitro toxicity study to give the following concentrations by weight in the film: (i) 10% paclitaxel/no Pluronic; (ii) 10% paclitaxel/10% Pluronic; (iii) 10% paclitaxel/20% Pluronic; and (iv) a control film with no paclitaxel and no Pluronic. The PTX–Plu–PU film was entirely coated by a thin (70–80 μm) film of the polymeric material.



**Fig. 1** The new-generation covered self-expanding metal stent with a paclitaxel-incorporated membrane (MSCPM-2). **a** Photograph of the expanded stent. **b** Schematic of the membrane in cross-section demonstrating the polytetrafluoroethylene (PTFE) membrane forming the inner layer and the polyurethane membrane containing the mixture of paclitaxel and Pluronic F-127 (PTX–Plu–PU) forming the outer layer. The Pluronic micelles facilitate a constant release of paclitaxel from the stent.

## Experimental animals

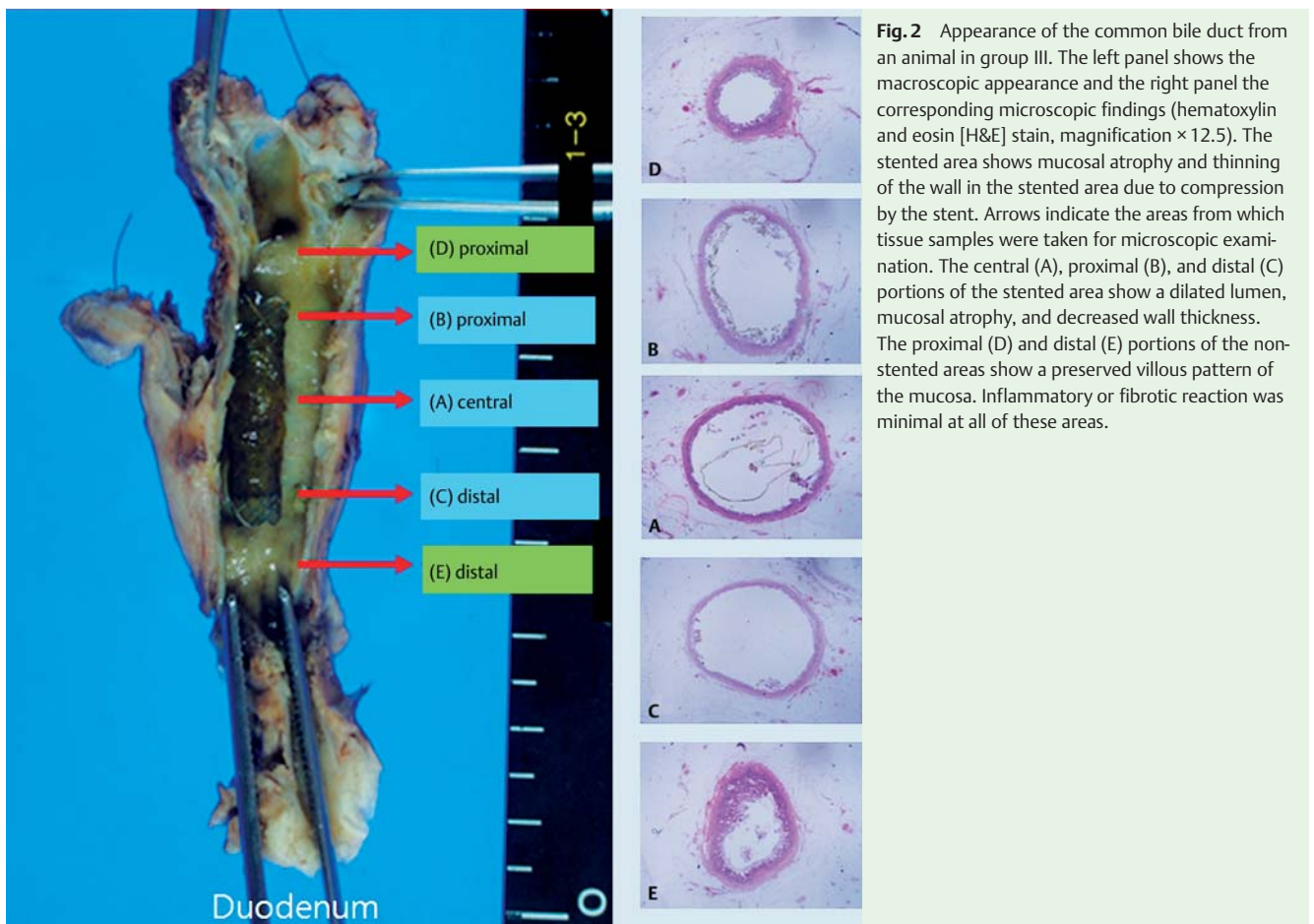
The in vivo experiments were performed using eight female domesticated mini-pigs with a mean weight of 42 kg. These animals were randomly divided into four groups and underwent insertion into their bile ducts of covered SEMSS coated with different proportions of Pluronic and paclitaxel as follows: group I, 0% Pluronic+0% paclitaxel; group II, 0% Pluronic+10% paclitaxel; group III, 10% Pluronic+10% paclitaxel; and group IV, 20% Pluronic+10% paclitaxel. Details of the eight experimental pigs are shown in ● Table 1.

## Stent insertion

The stents were inserted surgically with the bile duct approached via the duodenum. The pigs were anesthetized with 25 mg/mL tiletamin and 25 mg/mL zolazepam in a combined medication (Zoletil; Virbac, Carros, France) that was given by intramuscular injection as induction. During the operations, anesthesia was maintained by inhaled isoflurane. Once anesthetized, each pig's abdomen was opened to confirm the position of the duodenum. After an opening with a minimum size of approximately 0.5 cm had been made in the duodenum, the bile duct was cannulated with a catheter via the ampulla and a guide wire was advanced into the bile duct. The MSCPM-2 stent was deployed over the guide wire using fluoroscopic guidance and the opening in the duodenum was sutured with chromic catgut (#5–0). The ab-

Experimental group	Proportion of Pluronic and paclitaxel contained within the stent	Animal number	Color	Weight, kg
I	0% Pluronic + 0% paclitaxel	A-1	Black/yellow	40
		A-2	Black/yellow	43
II	0% Pluronic + 10% paclitaxel	B-1	Black/white	39
		B-2	Black	39
III	10% Pluronic + 10% paclitaxel	C-1	Black/yellow	42
		C-2	Black/white	40
IV	20% Pluronic + 10% paclitaxel	D-1	Black/white	46
		D-2	Black/yellow	45

**Table 1** Characteristics of the eight female pigs that underwent insertion of the new generation of biliary metal stents covered with a paclitaxel-incorporated membrane (MSCPM-2s) containing varying proportions of Pluronic and paclitaxel.



**Fig. 2** Appearance of the common bile duct from an animal in group III. The left panel shows the macroscopic appearance and the right panel the corresponding microscopic findings (hematoxylin and eosin [H&E] stain, magnification  $\times 12.5$ ). The stented area shows mucosal atrophy and thinning of the wall in the stented area due to compression by the stent. Arrows indicate the areas from which tissue samples were taken for microscopic examination. The central (A), proximal (B), and distal (C) portions of the stented area show a dilated lumen, mucosal atrophy, and decreased wall thickness. The proximal (D) and distal (E) portions of the non-stented areas show a preserved villous pattern of the mucosa. Inflammatory or fibrotic reaction was minimal at all of these areas.

dominal wall opening was sutured with chromic catgut (#2–0) and nylon (#1) to complete the operation.

### Extraction of specimens

Blood samples were withdrawn on days 0, 1, 3, 7, 14, and 28 after stent placement. Serum was separated immediately using a centrifugal separator, then preserved in a freezer at or below  $-60^{\circ}\text{C}$ . After an observation period of 4-weeks from insertion of the stents, the experimental animals were killed and specimens including the common bile duct (CBD) with the stent and a section of the duodenum were removed. The bile ducts were sutured just below the liver without removing the stents, with this end of the bile duct being indicated as proximal. The bile ducts were incised longitudinally, and each stent was gently removed from the bile duct. The resected specimens were preserved in 100% formalin for later pathologic examination.

All experimental procedures were performed in accordance with the rules of the Institutional Animal Care Committee and were approved by the Committee on Animal Research at Inha University and the Animal Protection Committee of the Korean government.

### Histologic analysis

The CBD was then cross-sectioned at five levels: the central, proximal, and distal portions of the stented area (A, B, and C, left panel in **Fig. 2**) and the proximal and distal portions of the non-stented area (D and E, left panel in **Fig. 2**). Photographs were taken of the macroscopic appearance, and each cross-sectioned specimen was immediately fixed in 10% buffered formalin.

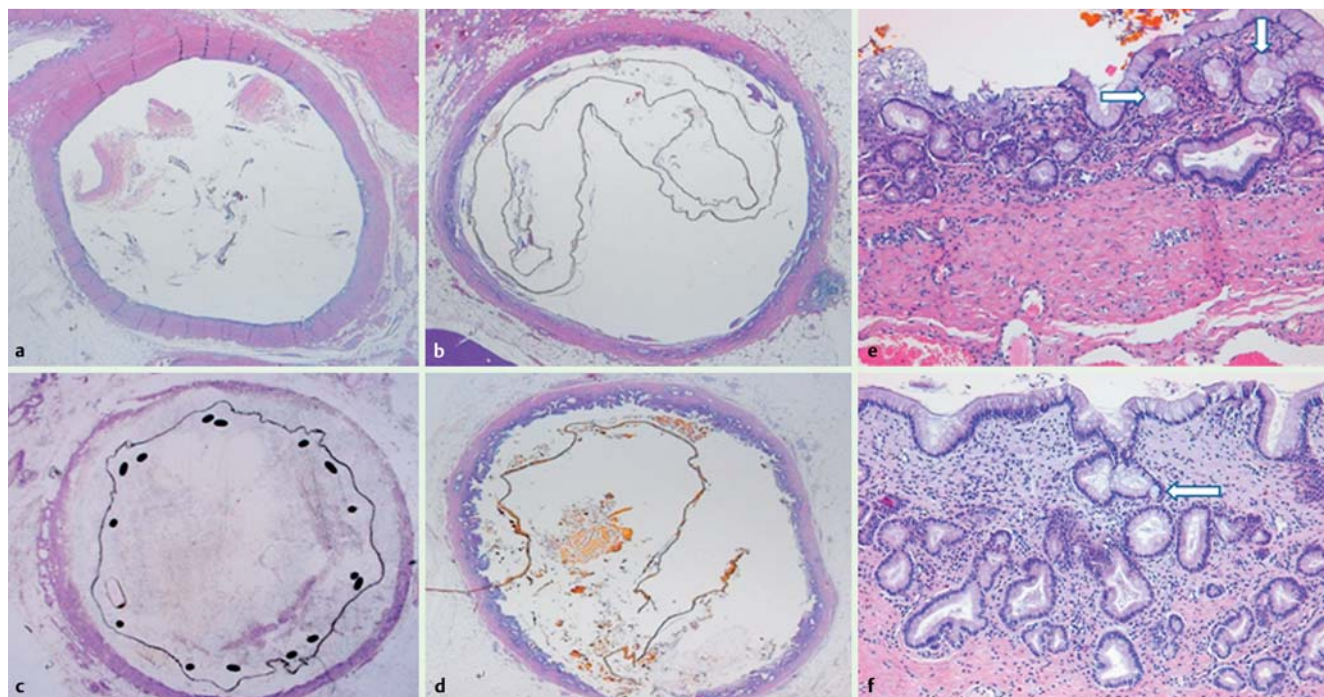
Each of the specimens was then sectioned and stained with hematoxylin and eosin (H&E) for microscopic examination. The severity of inflammation, fibrosis, mucosal sloughing, atrophy, and hyperplasia were evaluated in the central, proximal, and distal portions of the stented area (A, B, and C, right panel in **Fig. 2**) and the proximal and distal portions of the non-stented area (D and E, right panel in **Fig. 2**).

### Porcine serum analysis

The amount of paclitaxel released into the porcine serum was measured by high-performance liquid chromatography (HPLC) on days 0, 1, 3, 7, 14, and 28 after stent insertion. To prepare the samples, 20  $\mu\text{L}$  of internal standard material (4-butyl-benzoic acid, 1 mg/mL) was mixed with 1 mL of porcine serum sample that had been preserved at  $-60^{\circ}\text{C}$ . Methyl tertiary butyl ether (MTBE; 2 mL) was then added, mixed with the resulting solution and left in an ice-bath for 20 minutes. After this procedure, the mixture was vortexed and centrifuged. The supernatant was then filtered through a 0.45- $\mu\text{m}$  pore-size filter. A 10- $\mu\text{L}$  sample of the filtered fluid was analyzed by HPLC (flow rate, 1.0 mL/min; sample injection volume, 20  $\mu\text{L}$ ; lowest limitation, 0.05  $\mu\text{g}/\text{mL}$ ; methanol to water, 70:30 vol/vol; and time 12 minutes).

### In vitro drug release

To investigate the efficacy of drug release, stents coated with different concentrations of Pluronic and a fixed amount of paclitaxel were placed in phosphate-buffered saline solution for 6 weeks. The proportions in the three sets of PTX-Plu-PU-coated stents were as follows: (i) 0% Pluronic (polyurethane 720 mg + paclitaxel



**Fig. 3a–d** Microscopic appearances of hematoxylin and eosin (H&E)-stained sections of the common bile ducts (magnification  $\times 12.5$ ) showing similar histologic findings with dilated lumen, mucosal atrophy, and decreased wall thickness in an animal from: **a** group I with 0% Pluronic + 0% paclitaxel; **b** group II with 0% Pluronic + 10% paclitaxel; **c** group III with 10% Pluronic + 10% paclitaxel; **d** group IV with 20% Pluronic + 10% paclitaxel. **e,f** Microscopic appearances of the H&E-stained common bile duct from an animal in group III (magnification  $\times 200$ ) showing atrophy and sloughing with mild inflammation and occasional intestinal metaplasia (arrows) but no fibrosis in: **e** the central portion of the stented area; **f** the proximal portion of the non-stented area.

80 mg + Pluronic 0 mg); (ii) 10% Pluronic (polyurethane 640 mg + paclitaxel 80 mg + Pluronic 80 mg); (iii) 20% Pluronic (polyurethane 560 mg + paclitaxel 80 mg + Pluronic 160 mg). Four stents were used in each set and the amount of paclitaxel released was measured by HPLC (methanol to water, 70:30; flow rate, 1.0 mL/min; run time, 20 minutes; wavelength 227 nm; injection volume, 50  $\mu$ L). After completion of the drug-release study, the membrane surface was examined by scanning electron microscopy.

#### In vitro toxicity study

A cholangiocarcinoma cell line (SK-Cha-1) was incubated in a 96-well culture plate (Nunc, Rochester, New York, USA) with  $2 \times 10^4$  cells per well for 24 hours at 37 °C with 5% CO<sub>2</sub> to evaluate the concentration-dependent toxicity of the paclitaxel–Pluronic F-127 combination. Four circular PTX–Plu–PU films of the same size were manufactured with different amounts of Pluronic F-127 and paclitaxel, as previously described, and were inserted into the plate. After incubation for 24 hours, the number of cells that survived during incubation was estimated using a tetrazolium-based colorimetric (MTT) assay (590 nm) to assess cell viability.

#### Statistical analyses

Quantitative data from the in vitro drug release and toxicity studies were compared using Student's *t* test, with results expressed as mean  $\pm$  standard deviation. All data were analyzed using statistical software (SPSS, version 12.0; SPSS, Inc., Chicago, Illinois, USA). *P* values less than 0.05 were considered statistically significant.

## Results



### Outcome following stent insertion

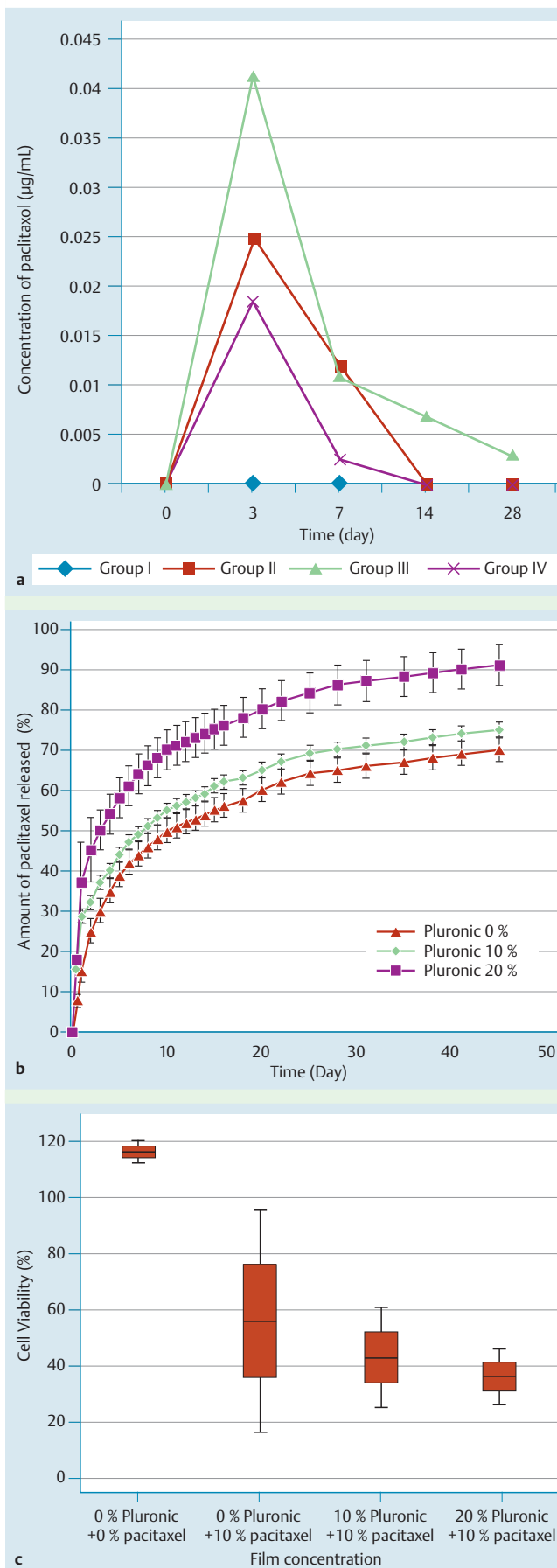
No animals experienced perforation or necrosis of the bile duct, or stent occlusion, and there were no deaths after stent insertion.

### Histologic changes

The appearances of the CBDs from the four animal groups were grossly similar 4 weeks after insertion of the stents. The areas which had been stented (A, B, and C, right panel in **Fig. 2**) had larger luminal diameters and thinner wall thicknesses than the non-stented areas (D and E, right panel in **Fig. 2**) because the stent widened the lumen by compressing the wall. The mucosal surfaces of the stented areas were flat and atrophic.

Microscopically, the stented areas showed thinning and sloughing of the mucosa due to compression by the stent compared with the non-stented areas (**Fig. 2**). However, inflammatory or fibrotic reactions were minimal in both the stented and non-stented areas.

The central portion of the CBD wall from each of the four animal groups showed similar histologic findings, which included a dilated lumen, mucosal atrophy, and decreased wall thickness (**Fig. 3a–d**). The CBD wall of the stented area revealed mild to moderate inflammation, mild or no fibrosis, and various degrees of mucosal sloughing and/or atrophy at high magnifications (**Fig. 3e**). Occasionally, intestinal metaplasia was detected. The non-stented area showed mild inflammation, mild or no fibrosis, and mild or no mucosal sloughing and/or atrophy (**Fig. 3f**).



### In vivo study of drug release

The total amount of paclitaxel released into the porcine serum over the 4 weeks was analyzed using HPLC. In group III (Pluronic 10%+paclitaxel 10%) released paclitaxel was detected for 28 days, but in groups II (0% Pluronic+10% paclitaxel) and IV (20% Pluronic+10% paclitaxel) released paclitaxel was observed for only 7 days (● Fig. 4a). In group I (0% Pluronic+0% paclitaxel), paclitaxel was not detected at any time. The amount of paclitaxel released in group III decreased with time. A similar tendency was observed in groups II and IV.

### In vitro study of drug release

The effects of our strategy of using nanoscale drug entrapment on the release of paclitaxel from the stents with a fixed concentration of paclitaxel (10% paclitaxel) and different concentrations of Pluronic are shown in ● Fig. 4b. When compared to the 0% and 10% Pluronic stents, 20% Pluronic stents provided much faster paclitaxel release. An initial burst of more than 30% paclitaxel release within the first day of experiment was observed from the 20% Pluronic stents, whereas no apparent burst of paclitaxel release occurred within the first day from the control and 10% Pluronic stents.

After 3 days, the amount of paclitaxel released from the 20% Pluronic stents was statistically more than from the 10% and 0% Pluronic stents (20% Pluronic stents vs. 10% Pluronic stents,  $P = 0.012$ ; 20% Pluronic stents vs. 0% Pluronic stents,  $P = 0.001$ ). After 10 days, the cumulative percentage of drug released from the 20% Pluronic stents was approximately 70%, and this was followed by a continuous release for approximately 50 days. In contrast, the cumulative percentages of drug released from the 10% Pluronic stents and 0% Pluronic stents were notably lower at 10 days (54% and 50%, respectively). A concentration of 10% Pluronic in the membrane exhibited a low initial burst and prolonged release behavior, while 20% Pluronic showed a high burst for 1 day.

### In vitro study of cell toxicity

The in vitro cancer cell viability test revealed that the toxicity of the PTX-Plu-PU films was increased only in the sets containing paclitaxel (10% paclitaxel/no Pluronic, 10% paclitaxel/10% Pluronic, 10% paclitaxel/20% Pluronic), with a tendency to more toxicity with higher concentrations of Pluronic F-127, although there were no statistically significant differences between the three sets that contained paclitaxel (● Fig. 4c).

**Fig. 4** a Mean serum concentrations of paclitaxel measured by high-performance liquid chromatography (HPLC) over a 28-day period in the four in vivo study groups (group I, 0% Pluronic + 0% paclitaxel; group II, 0% Pluronic + 10% paclitaxel; group III, 10% Pluronic + 10% paclitaxel; group IV, 20% Pluronic + 10% paclitaxel). Paclitaxel release was observed for 28 days in the animals of group III (10% Pluronic + 10% paclitaxel), whereas it was detected for only 7 days in groups II and IV. b In vitro cumulative release of paclitaxel measured by HPLC for the experimental stents with varying concentrations of Pluronic, showing the initial release profiles over the first 50 days. c Cell viability in the human cholangiocarcinoma cell line (SK-Cha-1) assessed by tetrazolium-based colorimetric (MTT) assay with varying concentrations of Pluronic, showing a tendency to increased toxicity in the cancer cells with increasing concentrations of Pluronic.

## Discussion

In our previous animal study [3], we showed that a metal stent covered with a paclitaxel-incorporated membrane (MSCPM) could be developed into a new and safe treatment modality in malignant biliary obstruction. A human pilot study using MSCPMs demonstrated acceptable levels of safety and effectiveness in patients with malignant biliary obstruction [5]. Although the safety of MSCPMs was reconfirmed in a multicenter prospective study [10], MSCPMs produced no significant differences in the duration of stent patency or survival time compared with non-drug-eluting covered metal stents. There seems to be two reasons for this. First, the membrane used in the MSCPMs was degraded by the flow of bile so that stent occlusion occurred due to tumor ingrowth through microcracks and holes in the stent before the paclitaxel could exhibit sufficient antitumor effects [7,8]. Second, the paclitaxel was not released steadily from the MSCPMs for a long enough time.

To overcome these problems, we developed a new-generation MSCPM-2 that has two improved characteristics. First, the membranes of the MSCPM-2 have a double-layer structure manufactured using PTFE to prevent degradation of the membrane by bile in the inner layer and a PTX-Plu-PU membrane in the outer layer. To suppress tumor ingrowth and progression, the long-term and continuous release of high concentrations of paclitaxel is necessary. For this purpose, Pluronic F-127 was applied to the drug delivery system in the new drug-eluting membrane. Paclitaxel can be incorporated into the core of polymeric micelles formed by Pluronic F-127 [11]. Because these micelles increase solubility, metabolic stability, and circulation time for paclitaxel [9], they facilitate the steady release of paclitaxel. Although applications of polymeric micelles in various drug delivery and gene delivery systems have been attempted [9], this study was the first trial to apply polymeric micelles to drug-eluting stents.

MSCPM-2s caused mild to moderate inflammation, mild or no fibrosis, and a variable degree of mucosal sloughing and/or atrophy in the CBD wall. This result was similar to our previous study [3] using MSCPMs, except that mucinous metaplasia and bile-duct thickening did not occur with the new stents. Metal stents have been reported to cause mucosal hyperplasia [12], inflammatory reaction [2], and extensive fibrosis [13] in bile ducts. Although MSCPMs reportedly caused significant mucosal hyperplasia compared with non-drug-eluting SEMSs in the canine biliary model, a relatively large diameter stent may have resulted in mechanical irritation causing mucosal hyperplasia via inflammation and fibrotic reactions [14].

If normal bile mucosa were irritated or injured by stent expansion, the antiproliferative effects of paclitaxel including the inhibition of fibroblasts [15,16] might reduce tissue hyperplasia by inhibiting tissue regeneration and stabilization [17]. Therefore, we postulate that the release of paclitaxel will be slower and longer-lasting in MSCPM-2s than in MSCPMs so that the antiproliferative effects of paclitaxel in MSCPM-2s will prevent mucosal hyperplasia more effectively. Moreover MSCPM-2s are safe because no significant complications such as tissue necrosis, cholangitis, or perforation were observed in any of the animals with the stent. Although MSCPM-2s were inserted by a surgical percutaneous transduodenal approach, the CBD was not injured and consequently methodological differences between peroral endoscopic and surgical stent placement should not cause histologic changes in the CBD.

In the *in vivo* study of drug release, the MSCPM-2 (10% Pluronic+10% paclitaxel) was shown to release paclitaxel for 28 days. We reported that a low level of paclitaxel ( $1.5 \times 10^{-2}$  to  $2.0 \times 10^{-1}$  mg/mL) released from MSCPMs was detected in the blood of patients for over 50 days in a human study (therapeutic range of paclitaxel  $0.9 \times 10^{-4}$  to  $1.1 \times 10^{-1}$  mg/mL) [5]. In the *in vitro* part of this study, MSCPM-2s released paclitaxel for over 50 days, which was similar to our previous study using MSCPMs (over 6 weeks) [3]. Our current study used a 10% (wt/vol) paclitaxel-incorporated membrane, which is the same concentration as in the previous human study [5], and used Pluronic F-127 for drug delivery, which will promote steady release of paclitaxel from stents. Therefore, we expect this will result in a lower blood concentration than previously achieved and believe this will extend the duration of release in future human studies.

It is important to obtain the optimal therapeutic effects from a locally applied chemotherapeutic agent on a stent, minimizing the systemic effect of the agent while maximizing its concentration within the bile duct. We previously reported the release profiles of paclitaxel from the polyurethane/Pluronic mixture membranes [4]. Although the duration of drug release of MSCPM-2s was similar to that of MSCPMs, the pattern of drug release was different between the two stents. The amount of the initial burst of paclitaxel release from MSCPMs was larger in stents covered with 10% (wt/vol) Paclitaxel than in stents covered with 20% Paclitaxel [3]. In contrast, the initial burst in MSCPM-2s was greater with 20% Pluronic. We assumed that the concentration of Pluronic F-127 in MSCPM-2s caused this result because the amount of paclitaxel released from the membrane increased as the concentration increased.

The *in vitro* study on drug release showed that the initial burst of paclitaxel release was greater when the concentration of Pluronic F-127 was higher and the amount of paclitaxel released decreased in line with the decrease in the concentration of Pluronic F-127. This finding indicates that the amount of paclitaxel released from MSCPM-2s can be controlled by regulating the concentration of Pluronic F-127. Moreover, in the *in vitro* study on drug toxicity, when the concentration of paclitaxel was fixed at 10% (wt/vol), the increased amount of paclitaxel released from the membrane in proportion to the concentration of Pluronic F-127 resulted in decreased cell viability.

In another human study [10] performed using drug-eluting stents containing 20% (wt/vol) paclitaxel, there were no serious complications, such as transmural necrosis, bile duct perforation, or systemic toxic effects including neutropenia or neurotoxicity, related to the high concentration of paclitaxel. Our study used a 10% (wt/vol) paclitaxel-incorporated membrane so that serious complications related to paclitaxel should not occur in future human studies. The addition of Pluronic F-127 is also not expected to cause any systemic toxic effect in future human studies because the agent will result in a slow release of paclitaxel and the total concentration of paclitaxel released from the MSCPM-2 will be the same as from the MSCPM. Therefore, an MSCPM-2 incorporating 10% (wt/vol) paclitaxel and 10% Pluronic F-127 would seem to be suitable for human application because it will minimize cell toxicity and maximize the effective release of paclitaxel. In conclusion, insertion of MSCPM-2s was shown to be as safe as MSCPMs in porcine biliary ducts, with no complications observed, indicating that MSCPM-2s can be used safely in clinical trials. The MSCPM-2 will require trials in humans to validate its significant benefits in terms of stent patency and drug delivery. However, further studies are needed to determine the optimal

paclitaxel and Pluronic F-127 ratio to maximize the effective release of the antitumor agent and to minimize toxicity to the bile duct.

**Competing interests:** The authors have no commercial associations that might be a conflict of interest in relation to this article. Tae-Woong Medical Company provided only free stents and scientific consultation, without any other support.

#### Institutions

- <sup>1</sup> Department of Internal Medicine, Gangnam Severance Hospital, Yonsei University College of Medicine, Seoul, Korea
- <sup>2</sup> Utah-Inha DDS & Advanced Therapeutics Research Center, Incheon, Korea
- <sup>3</sup> Department of Research and Development, Taewoong Medical Co., Ltd., Gimpo, Korea
- <sup>4</sup> Department of Biotechnology, The Catholic University, Bucheon, Korea
- <sup>5</sup> Department of Pathology, Inha University College of Medicine, Incheon, Korea
- <sup>6</sup> Department of Internal Medicine, Inha University College of Medicine, Korea

#### Acknowledgement

This research was supported by the grants from the Korean Health Industry Development Institute (KHIDI) and also by the National Center of Efficacy Evaluation for the Development of Health Products Targeting Digestive Disorders (NCEED).

#### References

- 1 Wagner HJ, Knyrim K, Vakil N et al. Plastic endoprosthesis versus metal stents in the palliative treatment of malignant hilar biliary obstruction. A prospective and randomized trial. *Endoscopy* 1993; 25: 213–218
- 2 Knyrim K, Wagner HJ, Pausch J et al. A prospective, randomized, controlled trial of metal stents for malignant obstruction of the common bile duct. *Endoscopy* 1993; 25: 207–212
- 3 Lee DK, Kim HS, Kim KS et al. The effect on porcine bile duct of a metallic stent covered with a paclitaxel-incorporated membrane. *Gastrointest Endosc* 2005; 61: 296–301
- 4 Lee DK. Drug-eluting stent in malignant biliary obstruction. *J Hepato-biliary Pancreat Surg* 2009; 16: 628–632
- 5 Suk KT, Kim JW, Kim HS et al. Human application of a metallic stent covered with a paclitaxel-incorporated membrane for malignant biliary obstruction: multicenter pilot study. *Gastrointest Endosc* 2007; 66: 798–803
- 6 Khan I, Smith N, Jones E et al. Analysis and evaluation of a biomedical polycarbonate urethane tested in an in vitro study and an ovine arthroplasty model. Part II: in vivo investigation. *Biomaterials* 2005; 26: 633–643
- 7 Hausegger KA, Thurnher S, Bodendorfer G et al. Treatment of malignant biliary obstruction with polyurethane-covered Wallstents. *AJR Am J Roentgenol* 1998; 170: 403–408
- 8 Kim JH, Song HY, Shin JH et al. Membrane degradation of covered stents in the upper gastrointestinal tract: frequency and clinical significance. *J Vasc Interv Radiol* 2008; 19: 220–224
- 9 Kabanov AV, Batrakova EV, Alakhov VY. Pluronic block copolymers as novel polymer therapeutics for drug and gene delivery. *J Control Release* 2002; 82: 189–212
- 10 Song TJ, Lee SS, Yun SC et al. Paclitaxel-eluting covered metal stents versus covered metal stents for distal malignant biliary obstruction: a prospective comparative pilot study. *Gastrointest Endosc* 2011; 73: 727–733
- 11 Abdullah AlN, Lee H, Lee YS et al. Development of disulfide core-cross-linked Pluronic nanoparticles as an effective anticancer-drug-delivery system. *Macromol Biosci* 2011; 11: 1264–1271
- 12 Bethge N, Wagner HJ, Knyrim K et al. Technical failure of biliary metal stent deployment in a series of 116 applications. *Endoscopy* 1992; 24: 395–400
- 13 Huibregtse K, Carr-Locke DL, Cremer M. European Wallstent Study Group. et al. Biliary stent occlusion – a problem solved with self-expanding metal stents? *Endoscopy* 1992; 24: 391–394
- 14 Lee SS, Shin JH, Han JM et al. Histologic influence of paclitaxel-eluting covered metallic stents in a canine biliary model. *Gastrointest Endosc* 2009; 69: 1140–1147
- 15 Song D, Wientjes MG, Au JL. Bladder tissue pharmacokinetics of intravesical taxol. *Cancer Chemother Pharmacol* 1997; 40: 285–292
- 16 Van Os EC, Petersen BT, Batts KP. Spiral nitinol biliary stents in a porcine model: evaluation of the potential for use in benign strictures. *Endoscopy* 1999; 31: 253–259
- 17 Shin JH, Song HY, Choi CG et al. Tissue hyperplasia: influence of a paclitaxel-eluting covered stent—preliminary study in a canine urethral model. *Radiology* 2005; 234: 438–444